



PATIENT

Erika Animal Welfare Society

SPECIES

Feline

BREED

DSH

SEX

Female

AGE

5 months

WEIGHT

6.2lbs

INTERPRETED BY

Maggie Machen Lamy, DVM, DACVIM (Cardiology)

IMAGING PERFORMED BY

Mark van Campen, DVM

HOSPITAL NAME

Mississippi Mills Animal Hospital

REFERRING VET

Dr. van Campen

INVOICE

27806

DATE

12/5/22

PRESENTING CLINICAL SIGNS

History: Grade V/VI systolic HM found at presentation for OHE; murmur louder on right side. On gabapentin for scan.

ECHOCARDIOGRAM FINDINGS

2D, m-mode, color flow and doppler imaging is available. The left ventricular wall is normal in dimension. The LV chamber is borderline increased in diastole. A small restrictive VSD is seen on color flow imaging just below the aortic valve; confirmed on Spectral although not visualized on 2D. The shunt is left to right and high velocity (4.9m/s). No right to left flow identified. The left atrium is high normal in size. Normal aortic root. The right atrium is normal in size. The right ventricle appears normal. The MPA is normal. The mitral valve is normal in structure and mobility. Blood flow through the RVOT is normal in velocity. There is no pleural or pericardial effusion seen.

CARDIAC CHART

FELINE CARDIAC PARAMETERS	BODY WEIGHT (kg)	HR (BPM)	IVSd (cm) (Moise, Pipers)	LVIDd (cm) (Moise, Pipers)	LWVd (cm) (Moise, Pipers)	FS (%)	EF (%)
NORMAL PARAMETER	-----	150-240	0.35-0.55	<2 (mean 1.5)	3.5-0.55	35-67	80-100
PATIENT	2.83	NM	0.35	1.2	0.32	52	84
FELINE CARDIAC PARAMETERS	LA/AO (Boon)	LA/AO HEART BASE (Swe) (Abbott)	LA 2D short axis Base view (cm) (Abbott)		LVOT VEL (m/s)	RVOT VEL (m/s)	E max (m/s)
NORMAL	<1.5	<1.3	<1.2		<1.6	<1.3	<0.9
PATIENT	NM	1.3	1.1		1.1	0.95	NM

**Note: All measurements based upon multi-modal images and methods. An average value is reported.*
 Adapted from June Boon, Veterinary Echocardiography, 1998
 Abbott J & MacLean H JVIM 2006;20: 111-119, Moise et al. Am J Vet Res 47:1476, 1986. Pipers et al. Am J Vet Res 40:882, 1979.

INTERPRETATION OF THE FINDINGS & FURTHER RECOMMENDATIONS

The cause of the murmur is a restrictive perimembranous ventricular septal defect (VSD). The defect is small in dimension, with high velocity left to right flow. There is no evidence of left heart volume overload or relative pulmonic stenosis at this time. No additional issues are identified.

Small shunts in cats are often of minimal lifelong clinical significance; however, lifelong monitoring is advised. No cardiac medications are indicated at this time. Anesthetic risk is low, however mild IV fluid restriction is advised.

Recommend recheck in 1 year to screen for any progressive dilation. Monitor at home for any associated clinical signs, including respiratory changes or signs of a thrombus.



PATIENT

Erika Animal Welfare
Society

SPECIES

Feline

BREED

DSH

SEX

Female

AGE

5 months

WEIGHT

6.2lbs

INTERPRETED BY

Maggie Machen Lamy,
DVM, DACVIM
(Cardiology)

**IMAGING
PERFORMED BY**

Mark van Campen,
DVM

HOSPITAL NAME

Mississippi Mills
Animal Hospital

REFERRING VET

Dr. van Campen

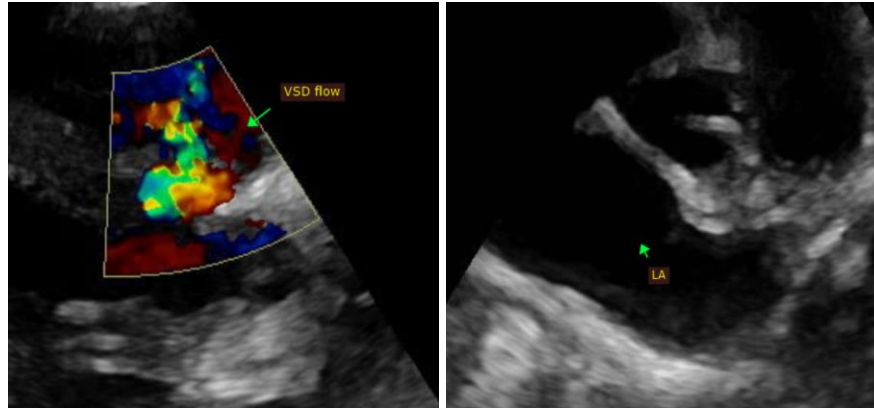
INVOICE

27806

DATE

12/5/22

IMAGES



The information and recommendations provided are based on the images presented by the referring veterinarian. No evaluation can be communicated regarding pathology that was not visible in the image/video clips provided.

Thank you for this referral. This report was generated using transcription software, and minor dictation errors may be present. If the clinical or image interpretation does not parallel your findings or if I can be of any further assistance, please contact me.

Maggie Machen Lamy, DVM
Diplomate of the American College of Veterinary Internal Medicine (Cardiology)
info@sonopath.com